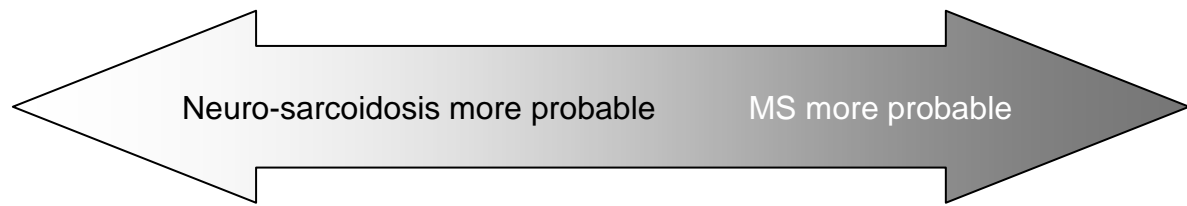


Tabel 9 Differentiatie van neuro-sarcoidosis en MS*



Clinical presentation

(bilateral) severe optic neuritis	unilateral, good prognosis
(bilateral) facial nerve palsy	uncommon

MRI features

continued enhancement of lesion	lesions enhancing < 2-4 weeks
meningeal enhancement	never
spinal cord lesions rare	spinal cord lesions typical

CSF

elevated protein	rare
oligoclonal bands local synthesis 37%	oligoclonal bands 95%
oligoclonal bands systemic synthesis 18%	rare

* No formal criteria exist. Indications of higher or lower probability are given, as found in relevant literature.